

# Hereditary hemochromatosis associated with autoimmune hemolytic anemia; A case report

Masih Falahatian<sup>1</sup>, Mohammad Reza Khosravi Farsani<sup>2</sup>, Ali Hajigholami

<sup>1</sup>School of Medicine, Isfahan University of Medical Sciences, Isfahan, Iran

<sup>2</sup>Cancer Prevention Research Center, Isfahan University of Medical Sciences, Isfahan, Iran

## Correspondence to:

Mohammad Reza

Khosravi Farsani, Email:  
drmohammadkhf@gmail.com

**Received:** 5 November 2018

**Accepted:** 10 January 2019

**ePublished:** 16 February 2019

**Keywords:** Hemochromatosis, Hemolytic anemia, Hereditary hemochromatosis, Autoimmune hemolytic anemia

## Abstract

Hereditary hemochromatosis is a disease associated with highly iron overload. This disease caused by genetic mutations inherited through family. Autoimmune hemolytic anemia is also an important autoimmune disease in which red blood cells (RBC) are destroyed mostly in spleen, extravascular hemolysis, and is related to secondary hemochromatosis. Here in this report, we report a 42-year-old woman diagnosed and treated as resistant autoimmune hemolytic anemia for almost 8 years and then diagnosed with hereditary hemochromatosis caused by HFE gene mutation (C282Y homozygous genotype). We suggest that in steroid dependent autoimmune hemolytic anemia cases, serum iron and ferritin measurements should be conducted regularly and a possible diagnosis of hereditary hemochromatosis or secondary hemochromatosis should be considered even if no familial history is existed.

**Citation:** Falahatian M, Khosravi Farsani MR, Hajigholami A. Hereditary hemochromatosis associated with autoimmune hemolytic anemia; A case report. J Prev Epidemiol. 2019;4(1):e02.

## Introduction

Highly absorbed irons in intestines and iron overload in solid organs and tissues is the most important characteristic of hereditary hemochromatosis (1). Hereditary hemochromatosis is known to have strong genetic basis with autosomal recessive or autosomal dominant inheritance and has a high frequency among northern European ancestry (2). Excessive body iron storage can cause different serious problems in patients with hereditary hemochromatosis including cirrhosis, hepatocellular carcinoma, heart failure, diabetes, hypogonadism and arthritis. Laboratory tests is very helpful for diagnosis of hereditary hemochromatosis which almost all of cases show increased serum ferritin and transferrin iron saturation more than 45% (3). Bacon and colleagues (2) believed that such measurements should be made on patients with chronically elevated liver enzymes. Next step for diagnosing of hereditary hemochromatosis is genetic assay for C282Y homozygous genotype known as HFE gene mutation in patients with iron overload. Additionally, liver biopsy can be helpful to evaluate severity of iron overload. Therapeutic phlebotomy is the most important treatment in hereditary hemochromatosis (4). Autoimmune hemolytic anemia is an important autoimmune disease in which

## Core tip

We suggest that in patients with long term, idiopathic, resistant autoimmune hemolytic anemia serum iron levels should be measured and possible hereditary hemochromatosis should also be considered even if no familial history of hereditary hemochromatosis is found.

immunoglobulin G (IgG) contributes to destruction of red blood cells (RBCs) by fixing complements and mostly in spleen. Autoimmune hemolytic anemia is diagnosed by evidences of extravascular hemolysis in laboratory data, existence of microspherocyte in peripheral blood smear (PBS) and positive direct Coombs test. Autoimmune hemolytic anemia can be associated with other autoimmune and lymphoproliferative diseases such as systemic lupus erythematosus and chronic lymphocytic leukemia. The most important treatment of autoimmune hemolytic anemia is systemic corticosteroids (5). The patient might also require several blood transfusions during the course of the disease. However, most of the cases benefit from splenectomy as the best and second line of treatment in steroid resistant or steroid dependent cases (6). Here in this case report, we present a unique case of a 42-year-old woman presented as persistent autoimmune hemolytic anemia for 8 years which also did not respond to splenectomy and later

diagnosed with hereditary hemochromatosis by checking the genetic markers. We suggest that physicians should be aware of possibility for co-existence of hereditary hemochromatosis in patients with resistant autoimmune hemolytic anemia.

### Case Presentation

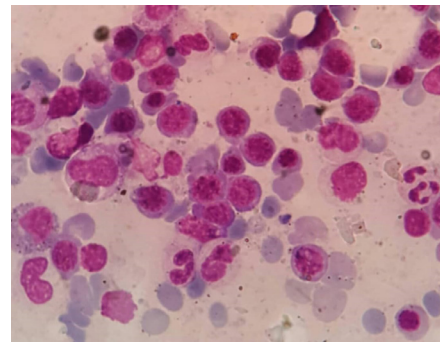
A 42-year-old woman was admitted in Al-Zahra hospital, Isfahan, Iran because of severe fatigue and anemia. She had a past medical history of long-term steroid dependent autoimmune hemolytic anemia for more than 8 years. Patients had various complaints mostly fatigue and jaundice about 8 years before admission. Her early laboratory findings indicated anemia and reticulocytosis along with positive result for direct Coombs test. Indirect bilirubin along with LDH levels were increased while haptoglobin level was decreased (Table 1). There were microspherocytosis, polychromasia and anisopoikilocytosis in peripheral blood smear, but no other abnormal RBCs such as schistocytes were detected. Additionally, Platelet and white blood cell count were normal without no other abnormal cells like blast or atypical lymphocyte (Figure 1). According to her past medical documents, other autoimmune diseases which could be coexisted with autoimmune hemolytic anemia such as SLE, antiphospholipid syndrome (APS) has been ruled out for the patient (Table 2). Chronic lymphocytic leukemia was also ruled out because no abnormality other than anemia was observed in laboratory data. Viral markers such as HIV ab was also negative (Table 2). The patient had no history of any drug administration such as penicillin. Thus, the diagnosis of idiopathic autoimmune hemolytic anemia had been ascertained for the patient. She had been then treated with high dose prednisolone (50 mg/d) first, which had been associated with clinical response. This treatment was tapered to 5 mg prednisolone daily, however, shortly after steroid tapering signs and symptoms of anemia developed while laboratory data showed recurrence of autoimmune hemolytic anemia. Then, the patient remained on steroids. In the past-history patient had received 5 units of pack cell for 4 times due to her severe anemia after the relapses. The last time of her transfusions was 4 years before her admission. In addition patient underwent splenectomy almost 4 years before admission, however she mentioned no gross remission in her symptoms. Bone marrow aspiration before splenectomy showed erythroid hyperplasia (Figure 2). Autoimmune hemolytic anemia relapsed after splenectomy, thus prednisolone with a dosage of 5 mg daily was continued after splenectomy until the time of recent admission. Presence of accessory spleen was also ruled out after her disease exacerbation by RBC scanning.

On admission, the patient had pale skin with mild icteric conjunctiva. She had no skin hyperpigmentation or rash, no lymphadenopathy, no arthritis with a normal liver span. Her initial laboratory tests revealed, alanine

**Table 1.** Complete blood count and laboratory data at the beginning of the symptoms, 8 years before admission

Laboratory data	Data
<b>Complete blood count</b>	
WBC (/mm <sup>3</sup> )	10400
Neutrophils (%)	53
Lymphocytes (%)	32
RBC (Mil/mm <sup>3</sup> )	1.51
Hemoglobin (g/dL)	6.1
Hematocrit (%)	16.2
MCV (fL)	110.1
MCH (pg)	31.8
MCHC (g/dL)	38.1
Reticulocyte count (%)	15%
Platelet (/mm <sup>3</sup> )	315000
<b>Blood chemistry</b>	
Albumin (g/dL)	4.3
ALT (U/L)	18
AST (U/L)	43
ALP (U/L)	315
Total bilirubin (mg/dL)	4.2
Direct bilirubin (mg/dL)	0.1
BUN (mg/dL)	11
Creatinine (mg/dL)	1.0
FBS (mg/dL)	94
LDH (U/L)	980
Direct coombs test	(+)
Haptoglobin (mg/dL)	8

WBC; white blood cell, RBC; red blood cell, MCV; mean corpuscular volume, MCH; mean corpuscular hemoglobin concentration, ALT; alanine transaminase, AST; aspartate transaminase, ALP; alkaline phosphatase, BUN; blood urea nitrogen, FBS; fasting Blood Sugar, LDH; lactate dehydrogenase.



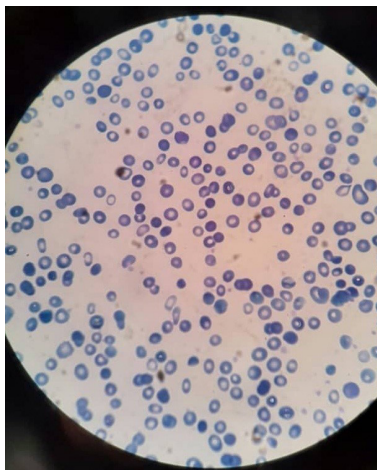
**Figure 1.** Peripheral blood smear indicating microspherocytosis, polychromasia and anisopoikilocytosis.

transaminase (ALT) and aspartate aminotransferase (AST) were mildly increased (119 and 72 U/L respectively), while from 8 years ago she had abnormal AST level due to hemolysis too. Total and direct bilirubin levels were mildly increased additionally (1.1 and 0.6 mg/dL respectively). Viral markers for viral hepatitis were also checked which indicated negative results. Abdominal ultrasonography was normal with no sludge in biliary duct (due to chronic hemolysis). Although Wilson disease is usually presented in patients under thirty, it was also ruled out as a possible differential diagnosis for hemolysis and abnormal liver

**Table 2.** Immunology and serology tests to rule out secondary autoimmune hemolytic anemia

Laboratory data	Data
<b>Immunology</b>	
Anti CCP (RU/mL)	1
Anti-dsDNA (IU/mL)	17
C-ANCA (U/mL)	Negative
P-ANCA (U/mL)	Negative
ANA (IF)	1/40
C3 (U/mL)	90
C4 (U/mL)	9
CH50 (U/mL)	160
RF QL (IU/mL)	1
VCA igM (U/mL)	Negative
HIV Ab (U/mL)	Negative
VDRL (U/mL)	Negative

Anti CCP; Anti-citrullinated protein antibody, Anti-dsDNA; Anti-double stranded DNA, ANA; Antinuclear antibody.



**Figure 2.** Bone marrow aspiration showing erythroid hyperplasia.

function tests (LFTs), by her ceruloplasmin level and urinary copper levels which were normal. Autoimmune hepatitis and celiac disease were also ruled out by checking serum protein electrophoresis, ASMA, anti-LKM antibody, anti-TTG-IgA and anti-TTG-IgG which were all normal. Primary biliary cirrhosis was also ruled out by normal AMA level (Table 3). Increased ferritin level (1248 mcg/dL), increased serum iron concentration (185 mcg/dL) and a normal total iron binding capacity (294 mcg/dL) were detected in laboratory data for diagnosing of possible hereditary hemochromatosis. The ratio of iron/ total iron-binding capacity (TIBC) was >50% (62.9%). These laboratory results are summarized in Table 4. In favor of hereditary hemochromatosis, a liver core biopsy was also conducted for the patient indicating grade 2/4 iron overload. Accordingly we conducted a genetic examination. The genotype was positive for HFE gene which indicative of hereditary hemochromatosis. Our case had an autosomal recessive mutation for HFE

**Table 3.** Tests for ruling out Wilson's disease, Primary Biliary cirrhosis, autoimmune hepatitis, Celiac disease and viral hepatitis

Tests	Data
Serum ceruloplasmin level (mg/dl)	24
Urine copper (µg)	38
AMA(U/mL)	1
ASMA (U/mL)	1
Anti LKM (U/mL)	1
Anti TTG-IgA (U/mL)	1
Anti TTG-IgG (U/mL)	1
HCV Ab	Negative
Hbs Ag	Negative

**Table 4.** Complete blood count and laboratory data at the time of admission

Laboratory data	Data
<b>Complete blood count</b>	
WBC (/mm <sup>3</sup> )	8000
Neutrophils (%)	43.8
Lymphocytes (%)	46.7
RBC (Mil/mm <sup>3</sup> )	2.4
Hemoglobin (g/dL)	8.1
Hematocrit (%)	24
MCV (fL)	99.2
MCH (pg)	36.7
MCHC (g/dL)	33.75
RDW-CV (%)	15.3
Platelet (/mm <sup>3</sup> )	429000
Retic count	8%
<b>Blood chemistry</b>	
Albumin (g/dL)	4.4
ALT (U/L)	119
AST (U/L)	72
ALP (U/L)	355
Total bilirubin (mg/dL)	1.1
Direct bilirubin (mg/dL)	0.6
PT (s)	11
PTT (s)	38
INR	1.1
BUN (mg/dL)	12
Creatinine (mg/dL)	0.9
FBS (mg/dL)	110
Ferritin levels (mcg/dL)	1248
Iron (mcg/dL)	185
Total iron binding capacity (mcg/dL)	294
ESR 1 h (mm)	8

WBC: white blood cell, RBC: red blood cell, MCV: mean corpuscular volume, MCH: Mean corpuscular hemoglobin concentration, RDW: red cell distribution width, ALT: alanine transaminase, AST: aspartate transaminase, ALP: Alkaline phosphatase, BUN: blood urea nitrogen, FBS: fasting blood sugar, ESR: erythrocyte sedimentation rate.

gene. Her parents had heterozygote mutation for HFE gene and her siblings had no mutations. After diagnosis of hereditary hemochromatosis, further evaluation for iron overload damage in other organs was conducted. Electrocardiography had no arrhythmia. The echocardiography indicated an ejection fraction

(EF) of 60%. The patient underwent weekly treatment of therapeutic phlebotomy of 300 mL. After 10 weeks of treatments, a decreased iron level was detected. Fatigue was relieved completely too (Table 5).

### Discussion

Hereditary hemochromatosis is a rare hereditary disease causing iron overload and as a result, affecting on multiple organs. Here we presented a unique case of autoimmune hemolytic anemia associated with hereditary hemochromatosis. An important differential diagnosis of hereditary hemochromatosis is secondary hemochromatosis which is mostly caused by recurrent blood transfusion or chronic extravascular hemolysis (2) but our case is hereditary hemochromatosis according to her positive genetic tests. Low amounts of blood transfusion and also her chronic autoimmune hemolytic anemia were not considered sufficient to justify her iron overload and suspicion of secondary hemochromatosis. Recent evidence indicated that hemochromatosis, due to iron overload, can influence on immune system and reduce the number and activity of CD8 cells and the ratio of CD8/CD4 T-cells or impairs phagocytosis (7). As a result, the patient with iron overload will become susceptible to infections. There is also evidence of increased ferritin and hepcidin due to inflammatory responses (for example in autoimmune hemolytic anemia) through elevated inflammatory cytokines including IL-6 (8). Hpcidin is a peptide produced by hepatocytes and is a negative regulator of iron absorption in small intestines (9). As a result, iron absorption could be decreased but in contrast, iron overload in macrophages increases. Furthermore HFE gene mutation is assumed to be associated with an unknown MHC type 1 gene mutation which results in reduced CD8 cells (10). All these mechanisms cause reduced cytotoxic cell activity and an increase in CD4/CD8 ratio which possibly increase antibody secretion that in turn results in exacerbation of autoimmune hemolytic anemia (8, 9). Such mechanisms could be present in our case which might explain her resistance to steroids. Association of hereditary hemochromatosis and autoimmune hemolytic anemia was first reported by Wallerstein and Robbins (11) in 1953 and to date, no other case of such association has been reported. The most important note of this case is her persistent autoimmune hemolytic anemia which lasted for almost 8 years which was also steroid dependent. Besides, autoimmune hemolytic anemia did not respond to splenectomy. We could not find any relation between these two diseases but amazingly, our case responded to phlebotomy. Accordingly fatigue resolved, significantly. There have been case reports of hereditary hemochromatosis associated with other diseases too (12-14). For example, Wang et al (12) presented a 16-year-old girl diagnosed with Gilbert's syndrome and hereditary hemochromatosis with positive familial genetic results for hereditary hemochromatosis.

**Table 5.** Complete blood count and laboratory data after 10 weeks of phlebotomy

Laboratory data	Data
<b>Complete blood count</b>	
WBC (/mm <sup>3</sup> )	9800
Neutrophils (%)	67.6
Lymphocytes (%)	31.9
RBC (Mil/mm <sup>3</sup> )	2.67
Hemoglobin (g/dl)	8.5
Hematocrit (%)	26.1
MCV (fL)	98
MCH (pg)	31.83
MCHC (g/dl)	32.56
RDW_CV (%)	15.2
Platelet (/mm <sup>3</sup> )	368000
Retic count	6%
<b>Laboratory data</b>	
Albumin (g/dl)	4.2
ALT (U/L)	66
AST (U/L)	45
ALP (U/L)	210
Total Bilirubin (mg/dL)	0.5
Direct Bilirubin (mg/dL)	0.2
PT (s)	12
PTT (s)	39
INR	1.2
BUN (mg/dL)	12
Creatinine (mg/dL)	0.8
FBS (mg/dL)	109
Ferritin levels (mcg/dL)	921
Iron (mcg/dL)	150
Total iron binding capacity (mcg/dL)	280

WBC; white blood cell, RBC: red blood cell, MCV; mean corpuscular volume, MCH; Mean corpuscular hemoglobin concentration, RDW; red cell distribution width, ALT; alanine transaminase, AST; aspartate transaminase, ALP; alkaline phosphatase, BUN; blood urea nitrogen, FBS; fasting blood sugar.

However, our patient is a case of autoimmune hemolytic anemia along with mutation of HFE gene which also had no effects on other solid organs such as cardiac system or joints. Another case of novel hereditary hemochromatosis mutation presented with juvenile cataract was reported by Yamakawa et al (15). They suggested an association between hyperferritinemia and early cataract formation. Iron overload can result in serious problems such as heart failure and arthritis that requires treatment (1, 2). A case report of hereditary hemochromatosis had reported the beneficial use of iron chelators in a patient with hereditary hemochromatosis and heart failure which is considered as an appropriate modality in patients with hereditary hemochromatosis (16). However, our patient was treated routinely with phlebotomy.

### Conclusion

Taken together, we suggest that in patients with long term, idiopathic, resistant autoimmune hemolytic anemia

serum iron levels should be measured and possible hereditary hemochromatosis should also be considered even if no familial history of hereditary hemochromatosis is found. This case report is a unique case of coexistence of autoimmune hemolytic anemia and hereditary hemochromatosis. Our case had responded to phlebotomy. Her weakness and fatigue were relieved consequently.

#### Authors' contribution

MF; Data acquisition, Literature review and drafting of the manuscript. MRKF; drafting of the manuscript and final approval of the article. AH; data acquisition, literature review, and drafting of the manuscript. All authors read and signed the final paper.

#### Conflicts of interest

The authors report no conflicts of interest.

#### Ethical considerations

Ethical issues (including plagiarism, data fabrication, double publication) have been completely observed by the authors. The patient has given her informed consent regarding publication of this case report.

#### Funding/Support

None.

#### References

- Powell LW, Seckington RC, Deugnier Y. Haemochromatosis. *Lancet*. 2016;388(10045):706-16. doi: 10.1016/S0140-6736(15)01315-X.
- Bacon BR, Adams PC, Kowdley KV, Powell LW, Tavill AS. Diagnosis and management of hemochromatosis: 2011 practice guideline by the American Association for the Study of Liver Diseases. *Hepatology*. 2011;54(1):328-43. doi: 10.1002/hep.24330.
- Salgia RJ, Brown K. Diagnosis and management of hereditary hemochromatosis. *Clin Liver Dis*. 2015;19(1):187-98. doi: 10.1016/j.cld.2014.09.011.
- Sood R, Bakashi R, Hegade VS, Kelly SM. Diagnosis and management of hereditary haemochromatosis. *Br J Gen Pract*. 2013;63(611):331-2. doi: 10.3399/bjgp13X668410.
- Berentsen S, Sundic T. Red blood cell destruction in autoimmune hemolytic anemia: role of complement and potential new targets for therapy. *Biomed Res Int*. 2015;2015:363278. doi: 10.1155/2015/363278.
- Lechner K, Jäger U. How I treat autoimmune hemolytic anemias in adults. *Blood*. 2010;116(11):1831-8. doi: 10.1182/blood-2010-03-259325.
- Walker EM, Walker SM. Effects of iron overload on the immune system. *Ann Clin Lab Sci*. 2000;30(4):354-65.
- Cruz E, Melo G, Lacerda R, Almeida S, Porto G. The CD8+ T-lymphocyte profile as a modifier of iron overload in HFE hemochromatosis: an update of clinical and immunological data from 70 C282Y homozygous subjects. *Blood Cells Mol Dis*. 2006;37(1):33-9.
- Barcellini W. New insights in the pathogenesis of autoimmune hemolytic anemia. *Transfus Med Hemother*. 2015;42(5):287-93. doi: 10.1159/000439002.
- Porto G, De Sousa M. Iron overload and immunity. *World J Gastroenterol*. 2007;13(35):4707.
- Wallerstein RO, Robbins SL. Hemochromatosis after prolonged oral iron therapy in a patient with chronic hemolytic anemia. *Am J Med*. 1953;14(2):256-60.
- Wang X, Liu Y, Chang Y, Liu H, Wang P. Diagnosis and treatment of a 16-year-old Chinese patient with concurrent hereditary hemochromatosis and Gilbert's syndrome. *Eur J Med Res*. 2014;19(1):51. doi: 10.1186/s40001-014-0051-y.
- Zhang W, Lv T, Huang J, Ou X. Type 4B hereditary hemochromatosis associated with a novel mutation in the SLC40A1 gene: A case report and a review of the literature. *Medicine (Baltimore)*. 2017;96(38). doi: 10.1097/MD.00000000000008064.
- Dynowski W, Zwolińska-Wcisło M, Mach T. Hereditary hemochromatosis and mild unconjugated hyperbilirubinemia in patient with ulcerative colitis. *Przegl Lek*. 2012;69(11):1232-4.
- Yamakawa N, Oe K, Yukawa N, Murakami K, Nakashima R, Imura Y, et al. A novel phenotype of a hereditary hemochromatosis type 4 with ferroportin-1 mutation, presenting with juvenile cataracts. *Intern Med*. 2016;55(18):2697-701. doi: 10.2169/internalmedicine.55.6565.
- Tauchenová L, Křížová B, Kubánek M, Fraňková S, Melenovský V, Tintěra J, et al. Successful treatment of iron-overload cardiomyopathy in hereditary hemochromatosis with deferoxamine and deferiprone. *Can J Cardiol*. 2016;32(12):1574. e1-. e3. doi: 10.1016/j.cjca.2016.07.589.