

Evaluation of patients with cervical traumatic injuries: a study on concordance between the need for imaging assessment and referring the patients by physicians for imaging

Reza Mosaddegh^{ID}, Mehdi Rezaei, Shahram Babakrad^{ID}, Samira Vaziri, Gholamreza Masoomi

Department of Emergency Medicine, Iran University of Medical Sciences, Tehran, Iran

Correspondence to:

Shahram Babakrad,
Email: dr_babakrad@yahoo.com

Received: 7 September 2018

Accepted: 13 October 2018

ePublished: 9 November 2018

Keywords: Trauma, Cervical, NEXUS criteria, Distracting Injury

Abstract

Introduction: Of the many cases of cervical trauma, a small number of lesions are important, and therefore, in more than 98% of spinal imaging, no positive finding is observed. Moreover, evidence suggests the high frequency of requested radiographs for neck trauma in patients with multiple trauma.

Objectives: The aim of the study was to evaluate the results of radiographic assessment and CT scanning of cervical injuries in patients with multiple trauma with painful distracting injuries. We also determine the concordance between need for imaging assessment and referring the patients by physicians for imaging.

Patients and Methods: The study population included 244 multiple trauma patients presenting with or without painful distracting injury (PDI) and referred to one of the three general governmental hospitals in Tehran. All patients required neck radiologic evaluation according to Nexus criteria.

Results: Of the 244 patients under study, 68.8% had PDI and 31.2% had no PDI. The most of the damages associated with distracting injury were limb fractures and laceration or soft tissue damage. In total, 14 of 244 patients (5.7%) with cervical trauma suffered cervical fracture of which 6 cases (42.9%) had PDI that of those, the presence of PDI was the only known Nexus index for radiological assessment of the cervical spine only in 2 (14.3%). In 6 patients out of 14 with cervical fractures, the painful distracting injuries included limb fractures in 3 patients, laceration or soft tissue damage in 2 patients, and visceral injuries in 1 patient. Thus, of 14 patients with cervical neck fractures, 8 had no painful distracting injuries and 6 had painful distracting injuries.

Conclusion: A few patients with PDI – as an indication for cervical radiography – had cervical spine injuries. Therefore, the exploitation of the NEXUS criteria, especially PDI, cannot be a very precise and specific for requesting cervical radiography.

Introduction

The trauma to the spinal column has a heavy burden on the governments as well as a negative impact on social and economic development. In the United States alone, there are about 15 to 40 cases per million people in the community with these types of traumas, which lead to 12 000 cases of paraplegia, 400 deaths before hospital admissions and 1000 deaths after admission (1). Imaging plays a crucial role in evaluating spinal traumas. The evaluation and management of patients with trauma, quickly and appropriately, from diagnosis to treatment, can significantly reduce the neurological damage in the vital organs of the patient (2). Therefore, radiologists play an important role in detecting the presence or absence of these injuries (3). Basically, the reason for using imaging techniques in such traumas is as follows (4): 1) Detecting

Core tip

The trauma to the spinal column has a heavy burden on the governments as well as a negative impact on social and economic development. In this study, the aim of the study was to evaluate the results of radiographic assessment and CT scanning of cervical injuries in patients with multiple trauma having painful distracting injuries.

traumatic abnormalities and determine the characteristics of injury; 2) Estimating the severity of injury, the level of motor and sensory disability or the damage to the peripheral nervous system; and 3) Evaluating spinal cord structures and surrounding tissues. But the question is, when and from what kind of imaging technique can be the most profitable. Accordingly, various guidelines are presented. At the level of

Citation: Mosaddegh R, Rezaei M, Babakrad S, Vaziri S, Masoomi G. Evaluation of patients with cervical traumatic injuries: a study on concordance between the need for imaging assessment and referring the patients by physicians for imaging. J Prev Epidemiol. 2018;3(2):e18.



cervical lesions, there is still uncertainty about the benefits of x-ray radiography. Despite the few studies available, the superiority of using cervical CT in comparison with classical radiography is still evident in assessing abnormal neck changes following trauma. In order to reduce the amount of radiation to the patient, they should actually be selected for radiography. Cervical CT scans are broadly indicative in comparison with classic radiography in high-risk patients with the possibility of soft tissue damage such as cervical spinal cord (5).

In 2000, the study of NEXUS evaluated 34069 low risk patients for spinal cord injury and showed that the following indications should be available for the cervical injuries to be depicted: 1) Lack of tenderness in the posterior midline of the cervical spine; 2) Lack of focal neurologic lesions; 3) Normal condition of alertness; 4) Lack of evidence of intoxication; and 5) Lack of clinical evidence painful damage that may mistake determine cervical vertebral damage from soft tissue damage (6). In cases where all of these indicators exist, the patient does not need to perform x-ray radiography, because the possibility of spinal cord injury will be very low with a sensitivity of 99% and a characteristic of 12.9% (7). Using these indices before cervical spine imaging, a significant reduction (24%) was achieved in cervical CT cases (8). However, in cases where these indices are not measurable, cervical CT is necessary. Therefore, in severe traumas, there is a need for direct CT screening (9).

Of the many cases of cervical trauma, a small number of lesions are important, and therefore, in more than 98% of spinal imaging, no positive finding is observed (10). Moreover, evidence suggests the high frequency of requested radiographs for neck trauma in patients with multiple traumas (11). In contrast to classic cervical radiography, CT scan is also considered as a precision diagnostic tool that is roughly parallel to conventional imaging for some patients, especially in cases of decreased consciousness, otorrhea and epistaxis, and other manifestations of multiple trauma patients. On the other hand, in some patients with indication for CT scan, radiological evaluation should also be performed completely, especially in areas of neck with fracture or trauma, and thus radiography alone cannot detect these injuries (12).

Objectives

In this study, the aim of the study was to evaluate the results of radiographic assessment and CT scanning of cervical injuries in patients with multiple trauma with painful distracting injuries. We also determine the concordance between need for imaging assessment and referring the patients by physicians for imaging.

Patients and Methods

Subjects

The study population included multiple trauma

patients presenting with or without painful distracting injury (PDI) and referred to one of the three general governmental hospitals in Tehran. All patients required neck radiologic evaluation according to Nexus criteria. In this regard, change in alertness and lacks of PDI were the exclusion criteria. Sampling was done in a non-probable and sequential manner so that patients with PDI were included till the required sample size was provided. Initial information about the patients including gender, age, trauma mechanism, location of the lesion and painful area were collected through a special checklist of the study. All patients requiring cervical radiological evaluation based on Nexus criteria were included in the study. The pain position was classified according to its anatomical location. The goal was to answer the question of whether painful distracting injuries in the Nexus criteria are valuable in determining the candidates for cervical radiography assessment. In other words, is there a relationship between cervical fractures with painful distracting injuries?

Ethical issues

Human rights were respected in accordance with the Helsinki Declaration 1975, as revised in 1983. The informed consent was taken from the patients as well as from parents and first relatives. The study was approved by ethics committee of Iran University of Medical Sciences (Ethical cod# IR.IUMS.SMD.REC1396.9411307006). This study was conducted as the residential thesis of Shahram Babakrad in Iran University of Medical Sciences (Thesis# 2788).

Statistical analysis

For statistical analysis, results were presented as mean \pm standard deviation (SD) for quantitative variables and were summarized by absolute frequencies and percentages for categorical variables. Normality of the data was analyzed using the Kolmogorov-Smirnoff test. Categorical variables were compared using chi-square test or Fisher's exact test when more than 20% of the cells with expected count of less than 5 were observed. The quantitative variables were also compared with *t* test or Mann-Whitney U test. For the statistical analysis, the statistical software SPSS version 16.0 for Windows (SPSS Inc., Chicago, IL) was used. P values of 0.05 or less were considered statistically significant.

Results

In total, 244 patients with cervical trauma were included. The mean age of the patients was 36.14 ± 4.76 years old and in terms of sexual distribution, 198 cases (81.1%) were men and 46 cases (18.9%) were women. Of the 244 patients under study, 168 (68.8%) had PDI and 76 (31.2%) had no PDI. In terms of primary characteristics, including gender, age, trauma mechanism and Glasgow Coma Scale (GCS) on admission, there was no difference between the two groups with and without PDI (Table 1). Among the patients with PDI, all patients were planned for cervical

Table 1. Comparing baseline parameters between the patients with and without cervical fractures due to trauma

Item	Group with PDI (n = 168)	Group without PDI (n = 76)	P value
Gender, No. (%)			0.769
Male	135 (80.4)	63 (82.9)	
Female	33 (19.6)	13 (17.1)	
Mean age	36.31±19.38	35.97±17.63	0.446
Mean GCS	13.15±3.55	13.40±3.14	0.559
Mechanism of trauma, No. (%)			0.722
Motor accident	110 (65.5)	48 (63.2)	
Assault trauma	7 (4.2)	5 (6.6)	
Falling	43 (25.6)	20 (26.3)	
Others	8 (4.7)	3 (3.9)	

Abbreviations: PDI, painful distracting injury; GCS, Glasgow Coma Scale.

spine radiological assessment. In this regard, most of the damages associated with distracting injury were: different types of limb fractures in 76 cases (45.2%), laceration or soft tissue damage in 34 cases (20.2%), visceral damage in 14 cases (8.3%), crushing injuries in 12 cases (7.1%), burns in 12 cases (7.1%) and others types of injuries in 20 cases (11.9%) cases. In total, 14 of 244 patients (5.7%) with cervical trauma suffered cervical fracture of which 6 cases (42.9%) had PDI that of those, the presence of PDI was the only known Nexus index for radiological assessment of the cervical spine only in 2 (14.3%) (Figure 1). Other Nexus criteria in residual 4 patients included cervical midline tenderness in 3 patient and mild loss of consciousness in one patient. In 6 patients out of 14 with cervical fractures, the painful distracting injuries included limb fractures in 3 patients, laceration or soft tissue damage in 2 patients, and visceral injuries in 1 patient. Thus, of 14 patients

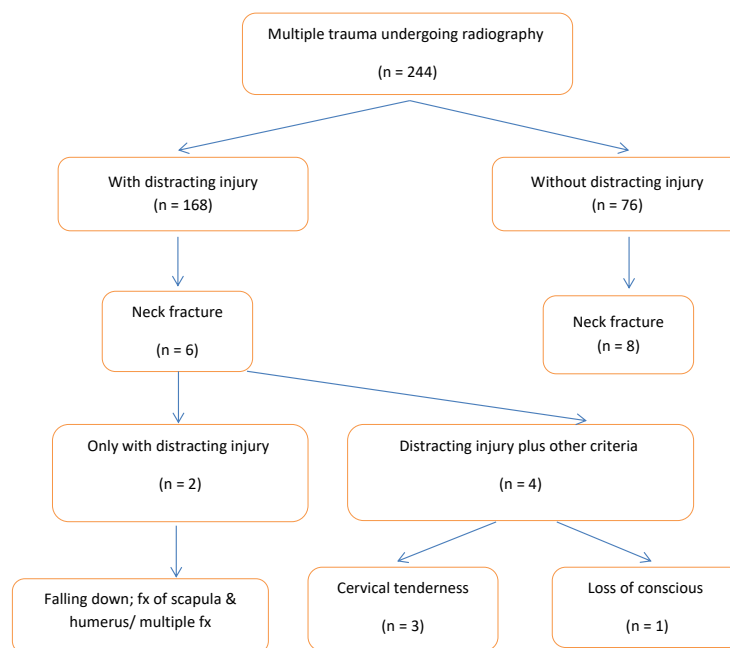
Table 2. Cervical injuries in patients with and without distracting injury

Item	Cervical fracture + PDI (n = 6)	Cervical fracture-PDI (n = 5)
C1	0	0
C2	2	2
C3	0	3
C4	0	0
C5	0	0
C6	2	2
C7	2	1

with cervical neck fractures, 8 had no painful distracting injuries and 6 had painful distracting injuries. In both groups of patients with and without painful distracting injuries, the cervical injuries localized more in C2, C6, and C7 (Table 2). Of 168 patients with multiple trauma with PDI, 13 patients had only PDI without any other criteria of NEXUS, which only 2 patients from 13 patients had cervical fracture (Figure 2).

Discussion

Correct management of patients with cervical trauma with or without spinal fracture depends directly on the trauma mechanism on one hand and the severity and pattern of involvement on the other. In this regard, the initial and precise clinical evaluation is the first step in assessing the severity of the lesions. In order to confirm or reject the initial clinical suspicion, the use of imaging approaches such as radiography, CT scan and, if necessary, magnetic resonance imaging (MRI) is also necessary. But it should be noted that the imposition of each of these imaging approaches will not only be accompanied

**Figure 1.** Diagram of patients with multiple trauma undergoing radiography.

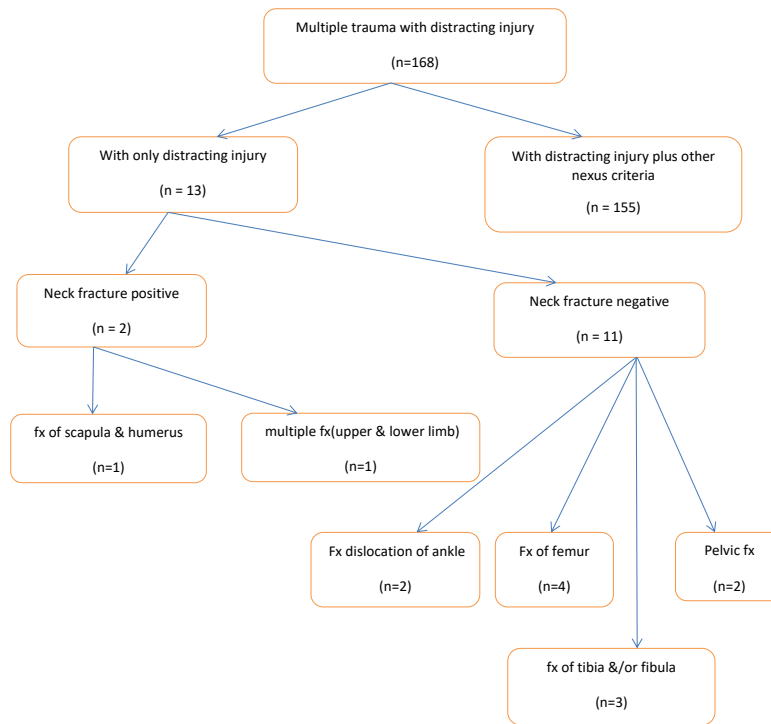


Figure 2. Diagram of patients with multiple trauma and painful distracting injury.

by high financial burden for the patient, but also with serious complications for them. Therefore, efforts are made to minimize unnecessary imaging of such patients. In this regard, new grading and evaluation systems have been developed that are a marker for the selection and need for imaging, the NEXUS evaluation system being one of the most practical and useful benchmarks. In this screening system, the presence of at least one of the following four indicators emphasizes requiring additional imaging assessment: the presence of neurological focal lesions, the presence of tenderness in the midline of the spinal cord, the presence of intoxication or the presence of distracting lesions. Therefore, it seems that using this system, the imperceptible requests for cervical imaging can be significantly reduced. But the fact is that in many studies, the number of unnecessary orders for imaging is significant.

The main point of the present study was that despite the fact that the majority of patients underwent radiography (including 168 out of 244 cases, 68.9%) had PDI, only 6 cases (2.5%) had fractures of the neck. In other words, cervical radiography was not necessary in 97.5% of patients, despite the presence of distracting injury. More interestingly, among the six people, in 2 cases, distracting injuries was the only Nexus criterion for indicating the patients for cervical radiological assessment. Finally, in the majority of patients with multiple trauma, even with PDI, the incidence of neck fractures is very unpredictable and therefore the presence of PDI and even other Nexus criteria cannot be a suitable criterion for being candidate for cervical radiography. Therefore, it's necessary to modify

the Nexus criteria to maximize its specificity for cervical trauma and fractures. In addition, considering that the most common causes of PDI in patients with cervical fractures include limb fractures especially upper limbs and then soft tissue damage, more attention to the PDI criterion as a marker of neck fracture should be focused on the presence of damage and fracture of the upper limbs. In a study by Velmahos et al (13), 549 alert patients with blunt trauma without cervical signs were included. All patients were negative in the clinical examination. Of these patients, only 14.2% were evaluated by CT or MRI, in which case no detection of cervical spine injury was made, but 1.3% of patients were admitted to the hospital for no reason and no special cervical damages. Therefore, in his study, the cases with unnecessary radiological assessment was shown to be 14.2%. Also, in a study by Ullrich et al in 2001 (14), of the 778 traumatic patients, 34% had painful distracting injuries, with the greatest damage to limb fractures (58%) and soft tissue damages (16%). In his study, cervical damage with PDI was only detectable in 5% of patients. In general, it seems that in order to reduce unnecessary applications for radiography, along with modifying the NEXUS criteria, training the students and assistants about NEXUS criteria along with their knowledge about the complications of imaging modalities is essential.

Conclusion

To conclude, it can be noted that only a few patients with PDI – as an indication for cervical radiography – had cervical spine injuries. Therefore, the exploitation of the NEXUS criteria, especially PDI, cannot be a very precise

and specific for requesting cervical radiography. Major distracting injuries simultaneous with cervical vertebrae fractures are upper limb fractures and then soft tissue laceration or damage, thus for attempting to modify the NEXUS criteria, these injuries can be further addressed.

Study limitations

During the research, we encountered some problems such as inconsistencies in implementation and time constraints.

Authors' contribution

MR and BSH designed the study, observed accuracy and validity of the study. VS and MGH collected the data and followed the study. MR, RM, BSH and FM supervised the project. MR and BSH wrote the paper. All authors edited and revised the final manuscript and accepted its publication.

Conflicts of interest

The authors declared no competing interests.

Ethical considerations

Ethical issues (including plagiarism, data fabrication, double publication) have been completely observed by the authors.

Funding/Support

The authors declare that there is no source of funding for the research reported.

References

1. Pneumaticos SG, Triantafyllopoulos GK, Giannoudis PV. Advances made in the treatment of thoracolumbar fractures: current trends and future directions. *Injury* 2013;44:703–12. doi: 10.1016/j.injury.2012.12.005
2. Griffith B, Bolton C, Goyal N, Brown ML, Jain R. Screening cervical spine CT in a level I trauma center: overutilization? *AJR Am J Roentgenol*. 2011;197:463–7. doi: 10.2214/AJR.10.5731
3. Hanson JA, Blackmore CC, Mann FA, Wilson AJ. Cervical spine injury: a clinical decision rule to identify high-risk patients for helical CT screening. *AJR Am J Roentgenol*. 2000;174:713–17.
4. Saltzherr TP, Fung Kon Jin PH, Beenen LF, Vandertop WP, Goslings JC. Diagnostic imaging of cervical spine injuries following blunt trauma: a review of the literature and practical guideline. *Injury* 2009;40:795–800. doi: 10.1016/j.injury.2009.01.015
5. Holmes JF, Akkinepalli R. Computed tomography versus plain radiography to screen for cervical spine injury: a meta-analysis. *J Trauma*. 2005;58:902–5. doi: 10.1097/01.TA.0000162138.36519.2A
6. Hoffman JR, Wolfson AB, Todd K, Mower WR. Selective cervical spine radiography in blunt trauma: methodology of the National Emergency X-Radiography Utilization Study (NEXUS). *Ann Emerg Med*. 1998;32:461–9. doi: 10.1016/S0196-0644(98)70176-3
7. Dickinson G, Stiell IG, Schull M, Brison R, Clement CM, Vandemheen KL, et al. Retrospective application of the NEXUS low-risk criteria for cervical spine radiography in Canadian emergency departments. *Ann Emerg Med*. 2004;43:507–14. doi: 10.1016/j.annemergmed.2003.10.036
8. Stiell IG, Wells GA, Vandemheen KL, Clement CM, Lesiuk H, De Maio VJ, et al. The Canadian C-spine rule for radiography in alert and stable trauma patients. *JAMA*. 2001;286:1841–8. doi: 10.1001/jama.286.15.1841
9. Berne JD, Velmahos GC, El-Tawil Q, Demetriades D, Asensio JA, Murray JA, et al. Value of complete cervical helical computed tomographic scanning in identifying cervical spine injury in the unevaluable blunt trauma patient with multiple injuries: a prospective study. *J Trauma*. 1999;47:896–902. doi: 10.1097/00005373-199911000-00014
10. Stiell IG, Wells GA, Vandemheen KL, Clement CM, Lesiuk H, De Maio VJ, et al. The Canadian C-spine rule for radiography in alert and stable trauma patients. *JAMA*. 2001;286:1841–8.
11. Macias BR, Murthy G, Chambers H, Hergens AR. Asymmetric loads and pain associated with backpack carrying by children. *J Pediatr Orthop* 2008;28(5):512–7.
12. Paluska TR, Sise MJ, Sack DI, Sise CB, Egan MC, Biondi M. Incidental CT findings in trauma patients: incidence and implications for care of the injured. *J Trauma*. 2007;62(1):157–61.
13. Velmahos GC, Theodorou D, Tatevossian R, Belzberg H, Cornwell EE 3rd, Berne TV, et al. Radiographic cervical spine evaluation in the alert asymptomatic blunt trauma victim: much ado about nothing. *J Trauma*. 1996;40(5):768–74.
14. Ullrich A, Hendey GW, Geiderman J, Shaw SG, Hoffman J, Mower WR. Distracting painful injuries associated with cervical spinal injuries in blunt trauma. *Acad Emerg Med*. 2001;8:25–9.